

**BOSTON
UNIVERSITY**



**BOSTON
MEDICAL**
CENTER

EXCEPTIONAL CARE. WITHOUT EXCEPTION.

Femoral Vein Transposition for Dialysis Access: How I Do It!

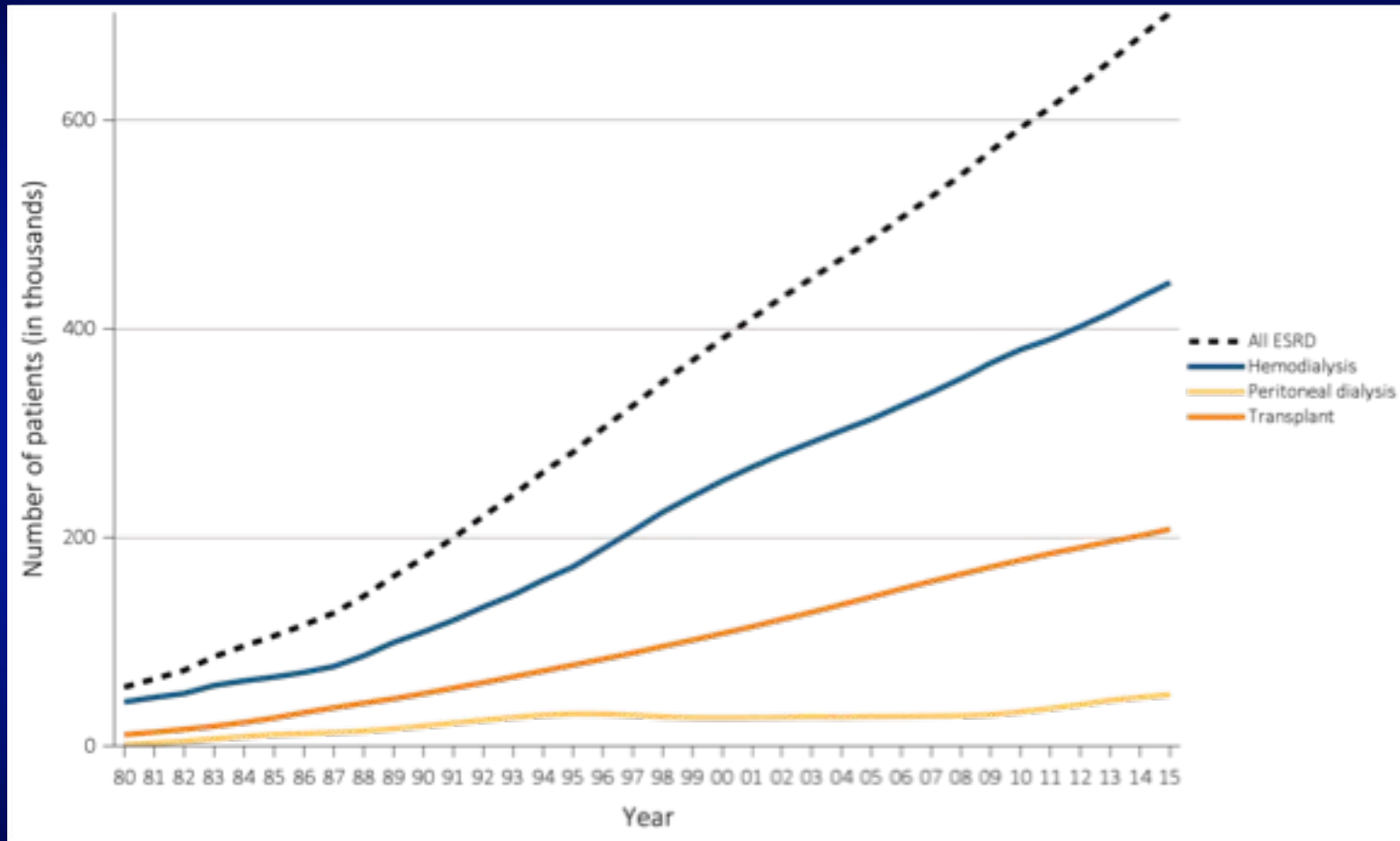
**Alik Farber, M.D.
Professor and Chief
Division of Vascular and Endovascular Surgery
Boston Medical Center
Boston University School of Medicine**

DISCLOSURE

Alik Farber

- No relevant financial relationship reported

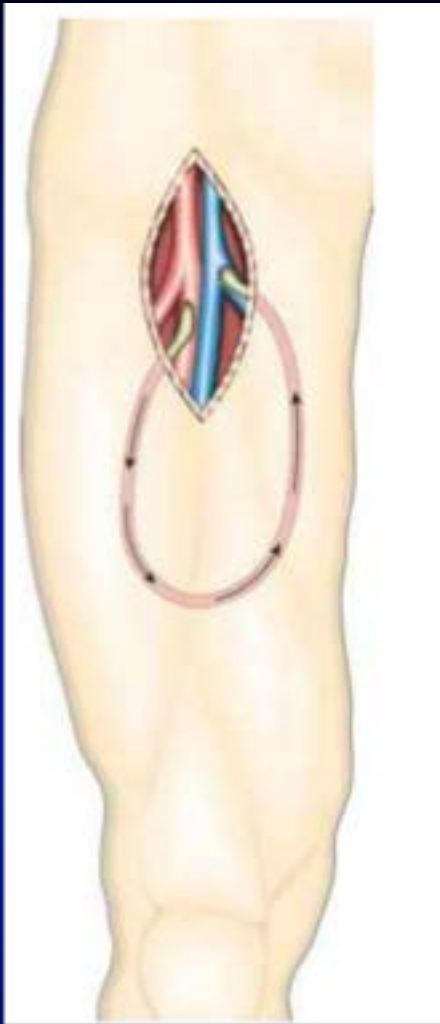
Prevalence of ESRD is increasing



Data Source: Reference Table D.1. Abbreviation: ESRD, end-stage renal disease. 2017 Annual Data Report

Background

- Access surgeons encounter ESRD patients who
 - developed recalcitrant central venous obstruction
 - have exhausted options for upper extremity access
- Lower extremity access is often the next option



REVIEW

Lower-extremity Arteriovenous Access for Haemodialysis: A Systematic Review

G.A. Antoniou^{a,b,*}, M.K. Lazarides^b, G.S. Georgiadis^b, G.S. Sfyroeras^a,
E.S. Nikolopoulos^b, A.D. Giannoukas^a

- **11 studies**
- **660 upper thigh prosthetic grafts**
- **48% *mean* primary patency at 1 year**
- **18.4% infection leading to graft loss**

Femoral Vein Transposition

- Described in 2000

- Huber T et al. *J Vasc Surg* 2000 **1 case**

- Jackson MR et al. *J Am Coll Surg* 2000 **2 cases**

- Popularized by Wayne Gradman

- Gradman WS et al. *J Vasc Surg* 2001, 2005 **55 cases**

Femoral vein transposition for arteriovenous hemodialysis access: Improved patient selection and intraoperative measures reduce postoperative ischemia

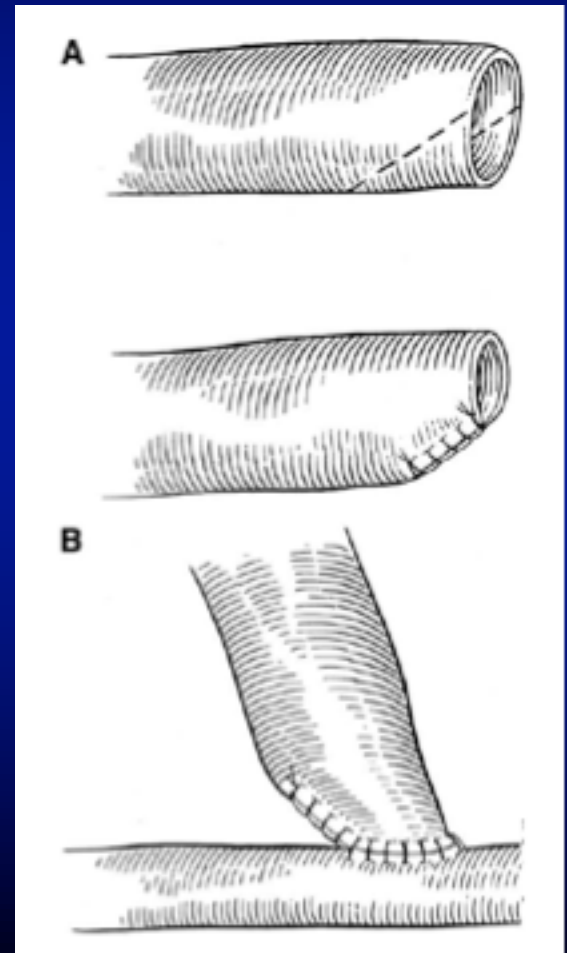
Wayne S. Gradman, MD, Judith Laub, MD, and William Cohen, MD, *Los Angeles, Calif*

Purpose: Construction of prosthetic arteriovenous access for hemodialysis in the thigh results in a high incidence of graft failure and infection. Autogenous femoral artery–common femoral thigh transposition (transposed femoral vein [tFV]) arteriovenous accesses have superior patency, but our previous report documented a high incidence of ischemic events requiring secondary surgical intervention. Recent results of improved patient selection and intraoperative maneuvers to reduce ischemia are unknown.

Methods: During a 6-year period eight children (mean age, 13.3 years) and 46 adults (mean age, 52.3 years; 27 female, 19 male) underwent construction of 55 tFV thigh accesses for hemodialysis access. Adult patients were divided into groups I and II on the basis of the introduction of specific strategies to reduce the incidence of ischemic complications. In the cohort of children, steal prophylaxis included one banded femoral vein, three tapered femoral veins, two distal femoral artery pressure measurements taken before and after access construction (mean ratio, 0.70), and two closed anterior and superficial posterior compartment fasciotomies. Of the first 25 accesses in adults (group I, mean age, 55.9 years), 10 had access banding (six at the initial procedure and four in the immediate postoperative period to treat ischemia). Of the second 22 accesses (group II, mean age, 48.2 years), steal prophylaxis included 14 tapered femoral veins, 6 distal femoral artery pressure measurements (mean ratio, 0.76; range, 0.62 to 0.86), and 1 fasciotomy. Patients with significant distal occlusive disease were not offered a tFV access in the time frame of group II.

Results: Eight accesses in children had 100% primary functional patency at 2 years, with no reoperations for ischemia. Nine group I adult patients underwent remedial procedures to correct distal ischemia. No adult patient in group II required a remedial procedure to correct ischemia. Groups I and II 2-year secondary functional access patency was 87% and 94%, respectively. There were no access infections in either group. Femoral vein tapering significantly reduced the need for remedial correction of ischemia ($P = .03$).

Conclusions: Improved patient selection and selective intraoperative femoral vein tapering eliminated remedial procedures to correct ischemia in patients undergoing tFV access. Patency rates were excellent despite the liberal use of vein tapering. Transposed FV access should be considered for good risk individuals undergoing their first lower extremity access. (*J Vasc Surg* 2005;41:279-84.)



No re-operation for ischemia
No access infections
94% 2 year secondary patency

Long-term results of femoral vein transposition for autogenous arteriovenous hemodialysis access

Pierre Bourquelot, MD,^{a,b} Marek Rawa, MD,^c Olivier Van Laere, MD,^b and Gilbert Franco, MD,^d *Paris and Neuilly sur Seine, France; and Meknès, Morocco*

Introduction: When all access options in the upper limbs have been exhausted, an autogenous access in lower limb is a

- 72 procedures (1984-2011)
- 13 (18%) patients had major cx (steal, bleeding, CHF)
 - → 6 ligated
- 59 (82%) of AVF matured
- Primary patency @ 9 yrs: 45%
- Secondary patency @ 9 yrs: 56%

to life-table analysis, the primary patency rates at 1 and 9 years were $91\% \pm 4\%$ and $45\% \pm 11\%$, respectively. The secondary patency rates at 1 and 9 years were $84\% \pm 5\%$ and $56\% \pm 9\%$, respectively.

Conclusions: Femoral vein transposition in the lower limb is a valuable alternative to arteriovenous grafts in terms of infection and long-term patency. Secondary venous percutaneous angioplasties may be necessary. High flow rates are frequently observed and patient selection is essential to avoid ischemic complications. (J Vasc Surg 2012;56:440-5.)


Current State of Affairs

- Femoral vein transposition is not commonly performed
 - Fear of major wound complications
 - Fear of ischemic steal
 - Fear of leg edema

Boston Medical Center

- Started to perform procedure in 2006
- Considered in patients who exhausted arm options
- Work up
 - Pre-operative femoral vein duplex and arterial non-invasive tests
- Exclude
 - frail and moribund patients
 - femoral vein occlusive disease
 - moderate-severe arterial ischemia

How I Do It!



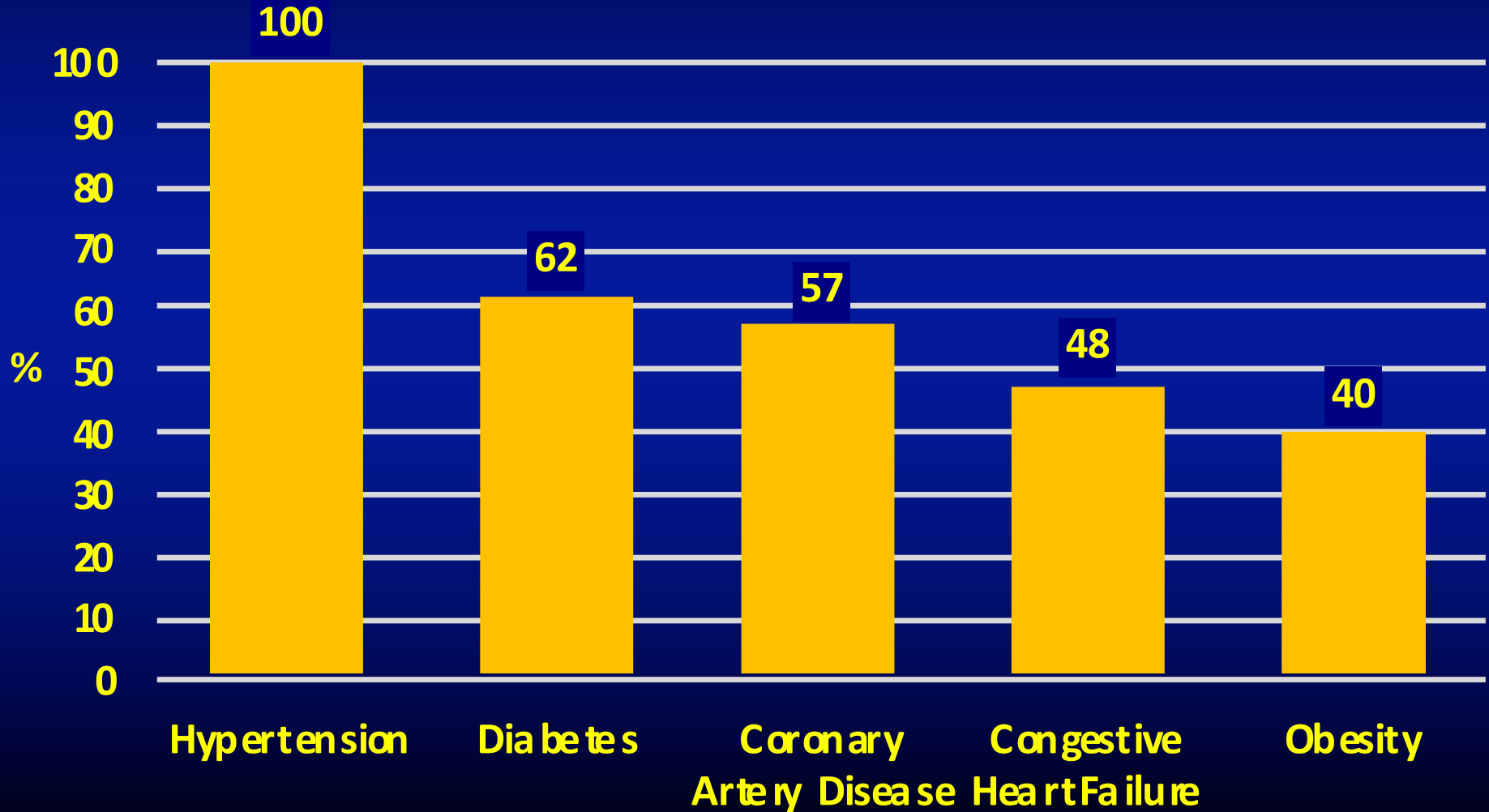
Boston Medical Center

- Retrospective study
- Femoral vein transpositions performed 2006 to 2017
- Demographics, comorbidities, vascular access history, perioperative and long-term outcomes were collected

Demographics

- 21 patients
- Mean age: 55 \pm 11 years
- 24% Female
- 75% African-American
- Mean BMI: 29 (17-46)
- 95% had prior arm access
 - 62% had > 3 prior AVF/AVG
 - 33% had > 4 prior AVF/AVG
- 100% were dialyzing via catheter

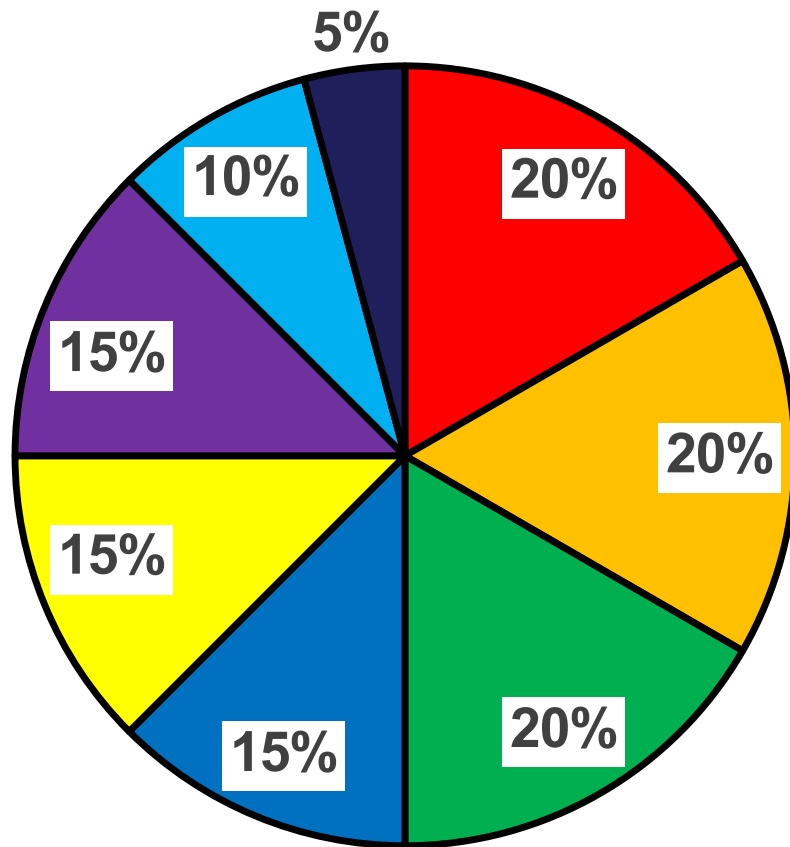
Comorbidities



Periprocedural Details

- Average pre-op ABI: 1.12
- Average pre-op femoral vein minimal diameter: 6.6 cm
- General anesthesia: 100%
- Median operative time: 250 mins
- Estimated blood loss: 141 mL
- Pre-anastomotic banding/tapering: 95% of cases

30 Day Post-operative Complications



- Hematoma
- Pulmonary
- Non-Surgical Site Infection
- Wound complication
- Gastrointestinal
- Cardiac
- Lower Extremity DVT
- Neurologic

Post-operative Outcomes

- **Return to the OR within 30 days**
 - 1 (5%) for thigh abscess
 - 1 (5%) for revision and thrombectomy
 - 1 (5%) for hematoma
 - 1 (5%) for open colectomy
- **Distal arterial ischemia (req revascularization): 1 (5%)**
- **Mortality**
 - 0 at 30 days
 - 1 (5%) at 90 days
- **Resource Utilization**
 - 2 readmissions
 - 3 ED visits

Maturation and Patency

- Maturation: 16/18 (89%) patients (followed > 6 months post-procedure) have successfully used FVT for HD
- Primary Patency at 1 year: 69%
- Secondary Patency at 1 year: 94%

Summary

- Femoral vein transposition can be successfully used in patients with limited dialysis options
- Self limited wound complications are common
- Ischemic steal is rare with anastomotic banding
- Maturation rates are high
- Patency rates are high

Conclusions

- Femoral vein transposition is a durable access that has a concrete role in the armamentarium of an access surgeon

