

# Vascular Ultrasound What to Order and Why

Jodi Wise BS, RVT

Vascular Lab Manager

Harborview Medical Center

PACIFIC NORTHWEST  
ENDOVASCULAR  
CONFERENCE

[PNEC-SEATTLE.ORG](http://PNEC-SEATTLE.ORG)

# DISCLOSURE

**Jodi Wise, BS, RVT**

- **No relevant financial relationship reported**

# Vascular Lab

- Registered Vascular Technologist
  - B.S., A.A.S
- Multiple Certifications
- Dedicated Vascular Lab
- IAC Accrediated



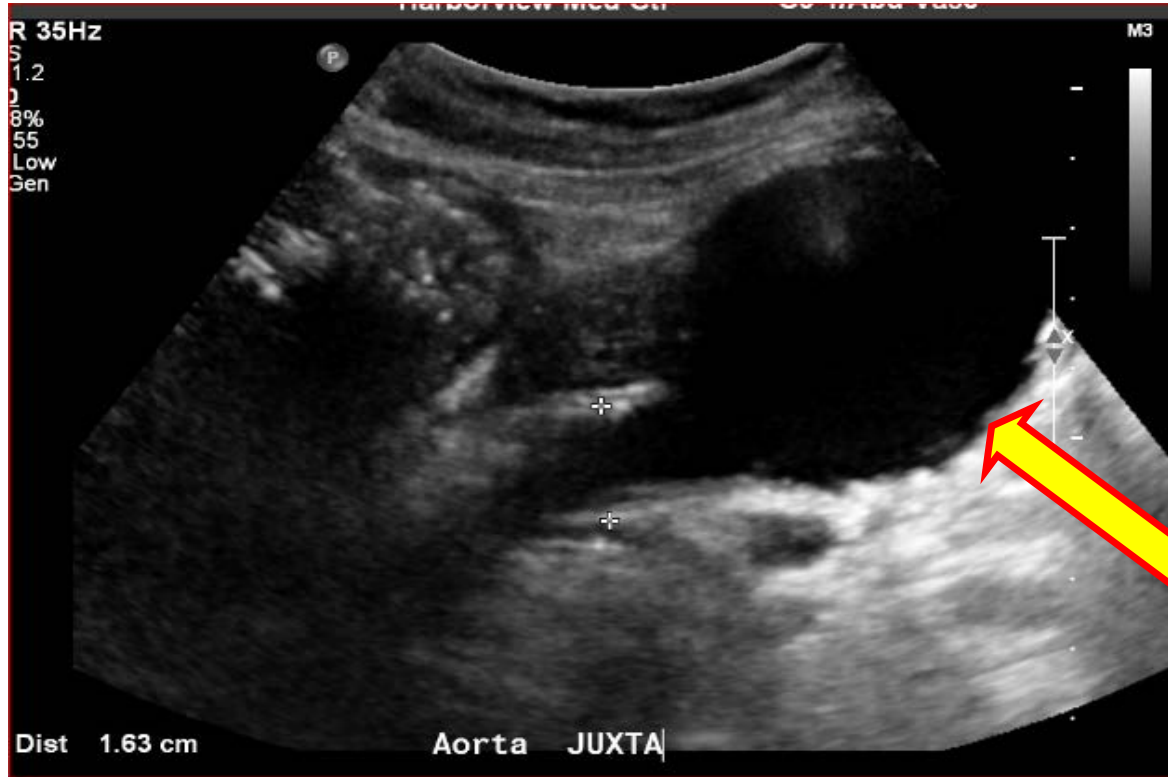# Peripheral Arterial Disease

- Ankle Brachial Index (ABI)
- Treadmill Test
- Toe Brachial Index (TBI)
- Lower Extremity Arterial Duplex

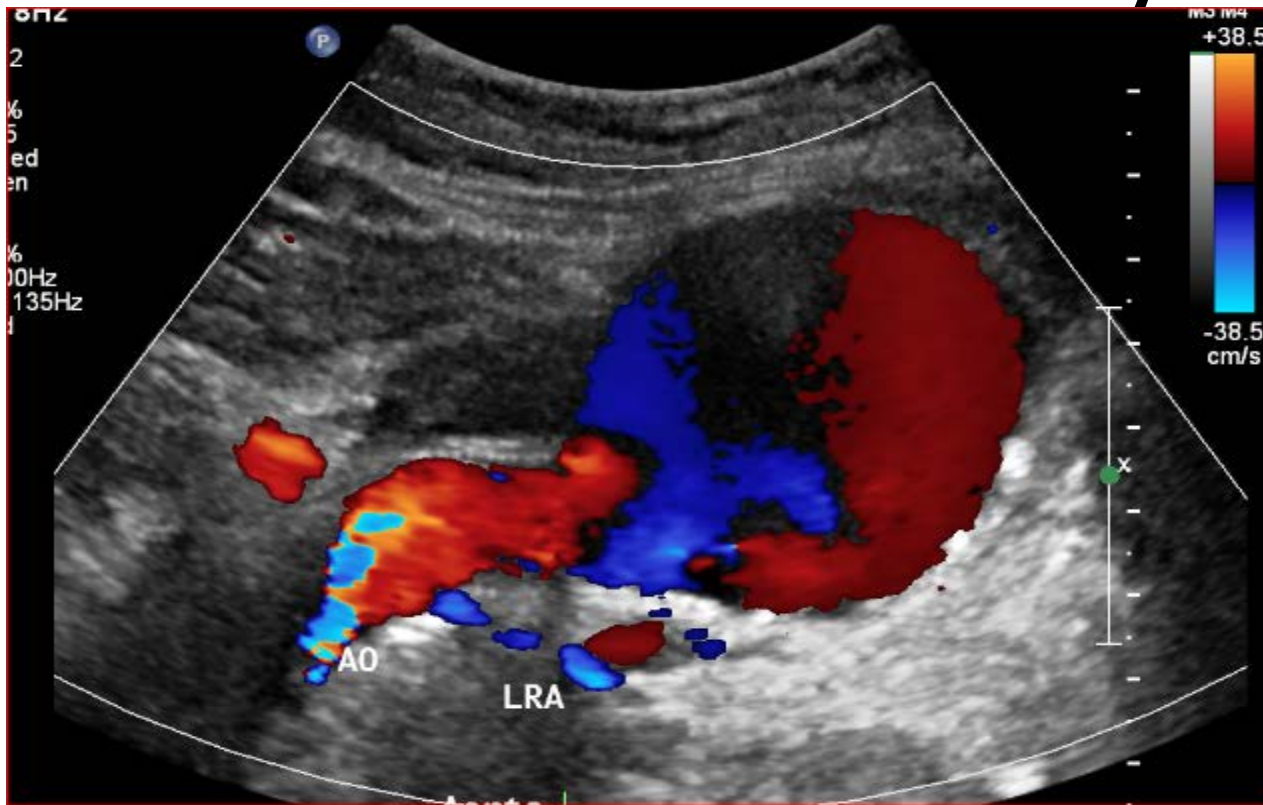
# Abdominal Aortic Aneurysm

- Screening Exam
- Iliac Aneurysm
- High Risk Patient
  - Smoker
  - Family History

# Abdominal Aortic Aneurysm

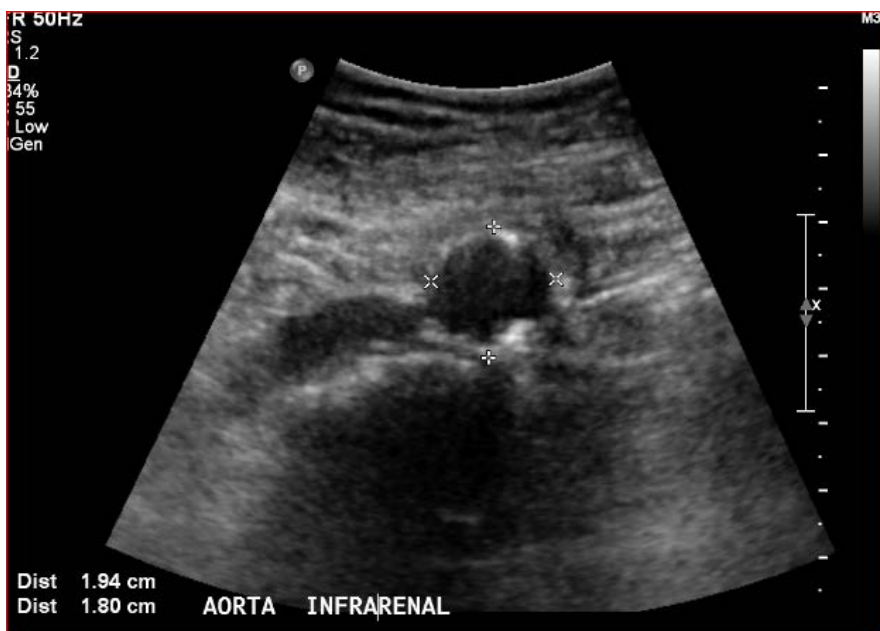

# Abdominal Aortic Aneurysm

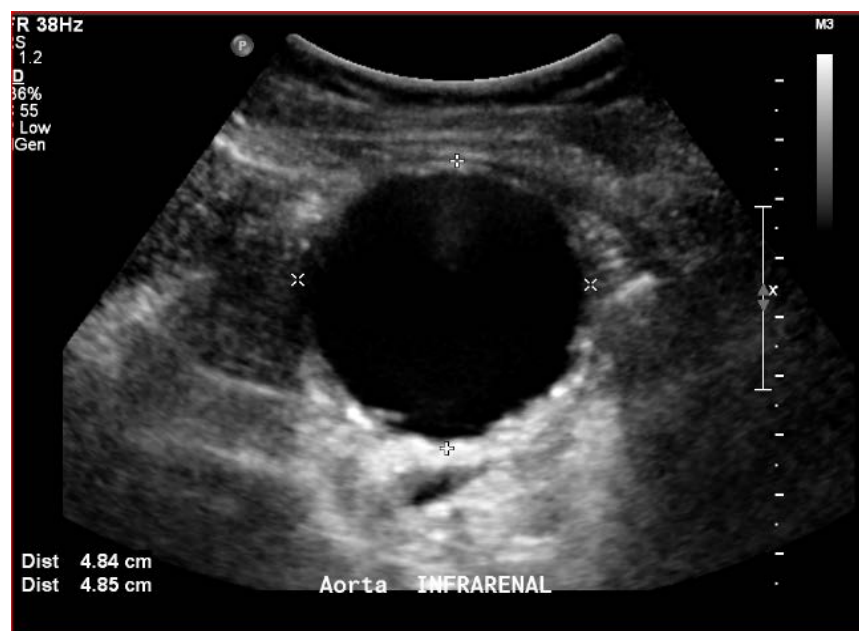


# Aorta

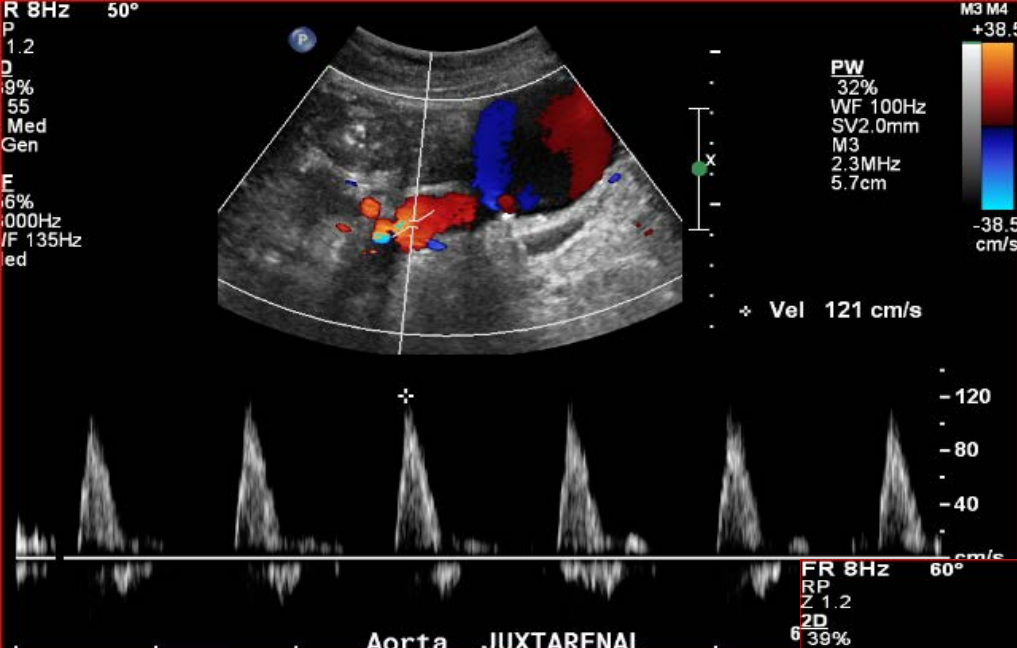
## Proximal



## Level of the Aneurysm

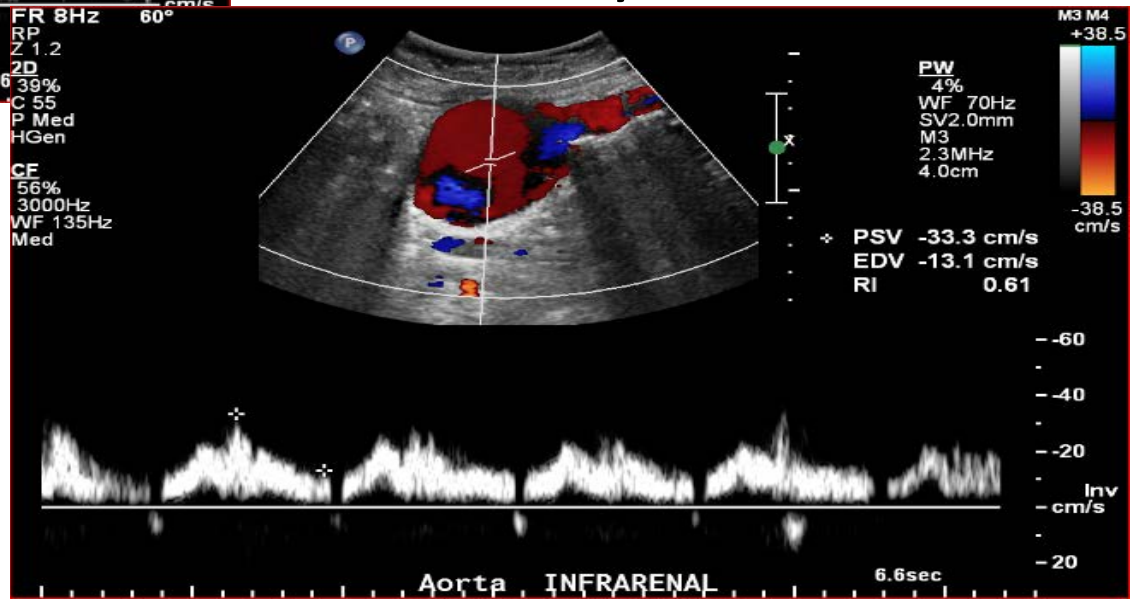






Normal Flow

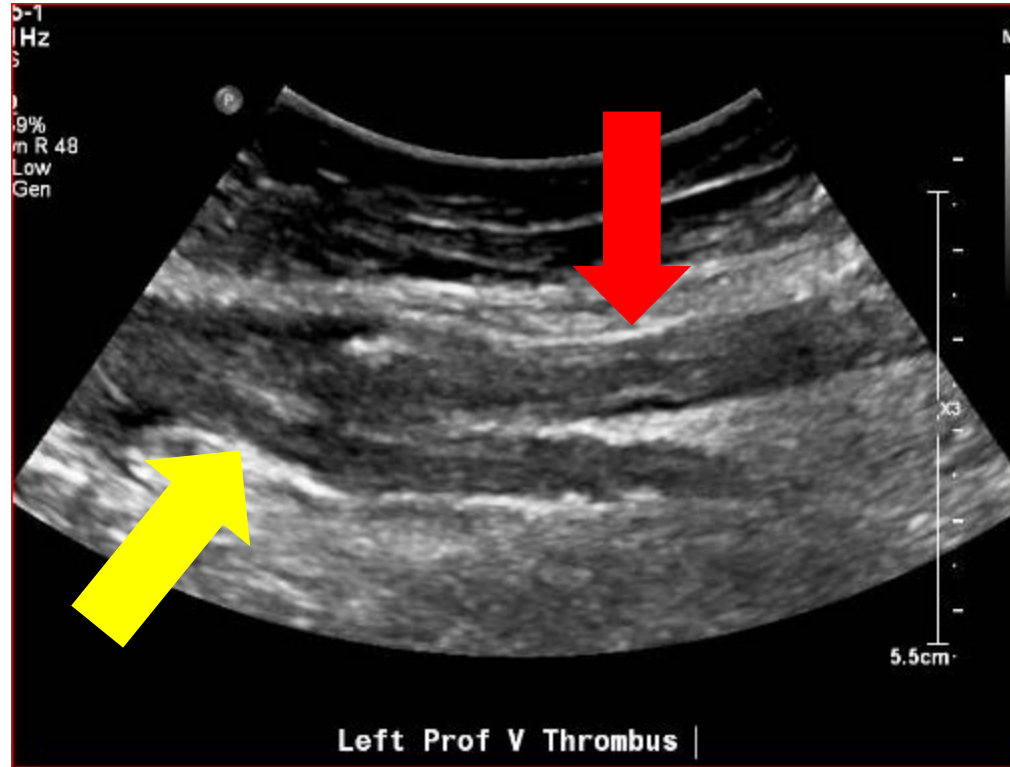
## Aneurysmal Flow



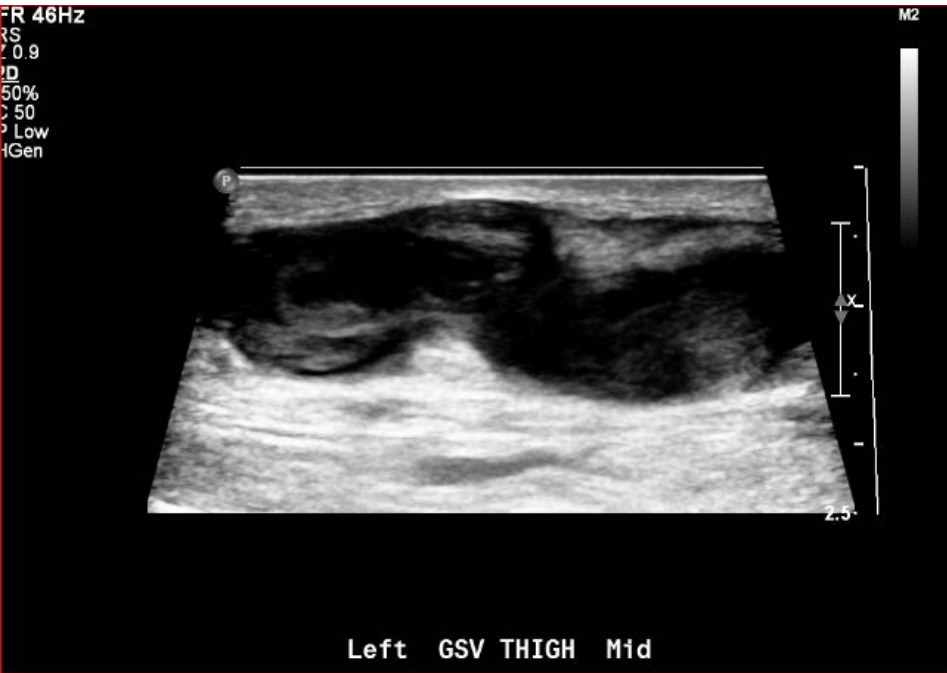# Deep Vein Thrombosis (DVT)

- Symptoms
  - Swelling
  - Immobility
  - Pain
  - Trauma
- Acute Stroke with Patent Foramen Ovale (PFO)

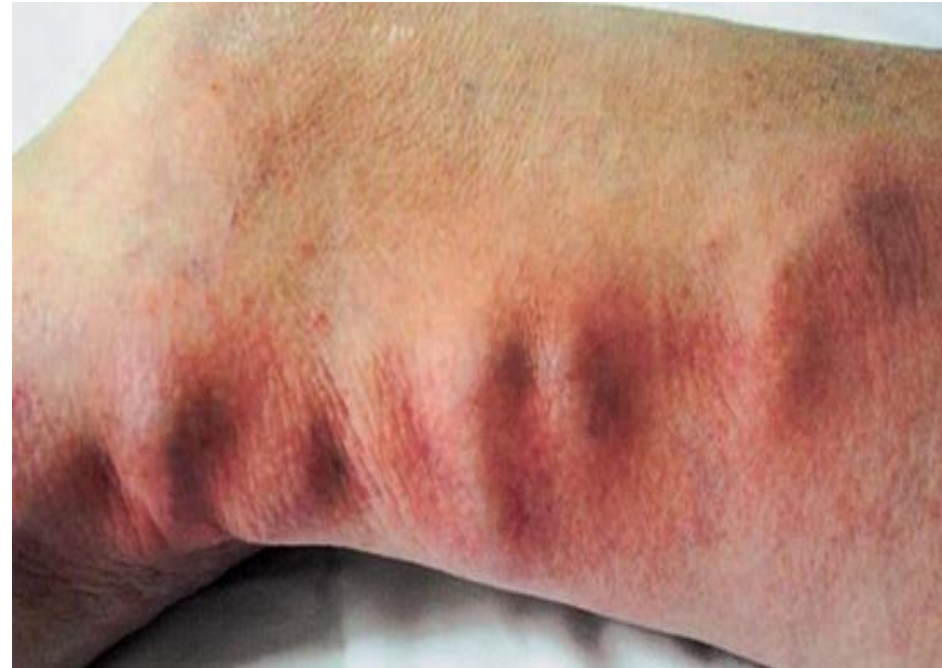# Deep Vein Thrombosis



# Superficial Thrombophlebitis



Thrombus in the Great Saphenous Vein

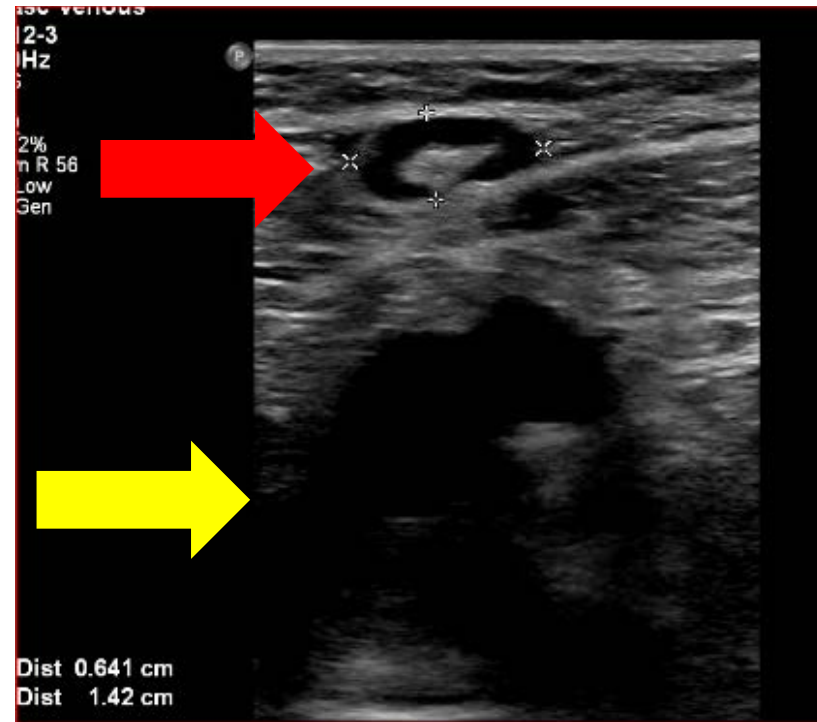


Palpable cord

Source- Nursing File.com

# Incidental Findings

- Enlarged Lymph Nodes
- Fluid Collection
- Muscle Tear
- Hematoma
- Mass



# Pre-operative Dialysis Mapping

## Arteries

- Blood Pressure
- Arterial Duplex
  - Stenosis/Calcification
- Evaluate Palmar Arch
  - Mitigate steal syndrome

## Veins

- Size
- Patency
- Anatomical Variation
- DVT
  - Superficial thrombophlebitis
  - Venous stenosis

# Dialysis Follow-up

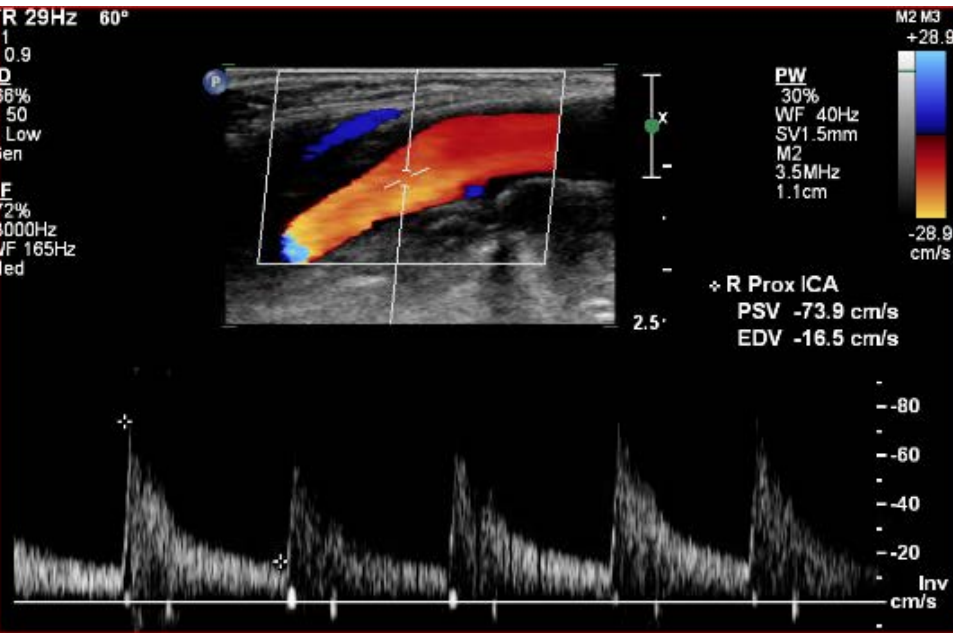- Fistula Patency
- Fistula Maturity
- Evaluate for stenosis
- Aneurysm/Pseudoaneurysm

# Carotid/Vertebral Artery

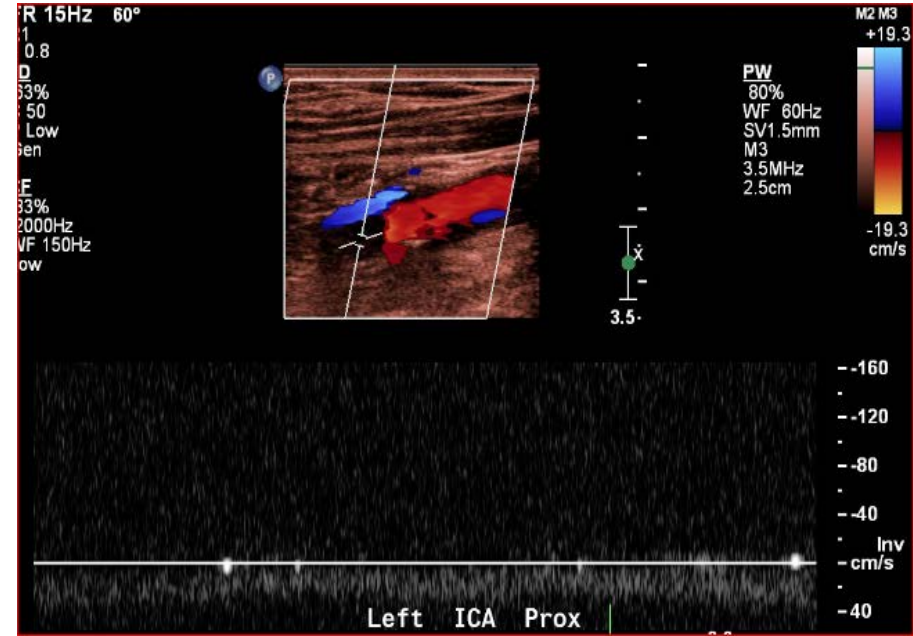
- CVA/TIA
- Bruit
- Visual Changes
- Dizziness
- Numbness/Weakness Arm and/or Leg



# Internal Carotid Artery



Normal Internal Carotid Artery



Occluded Internal Carotid Artery

# Vascular Injury

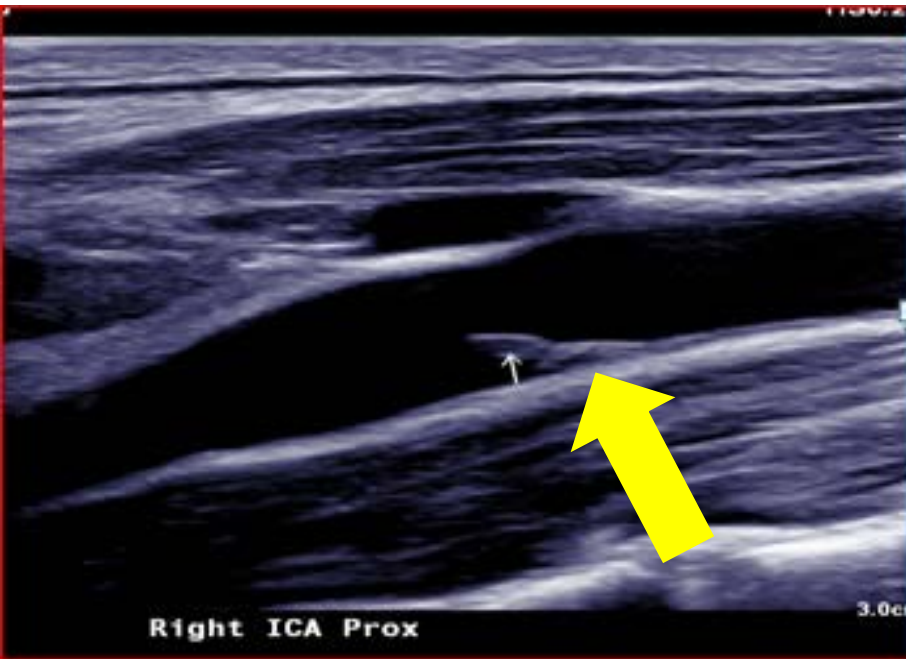
- Indications

- Trauma
  - Fracture
  - Blunt Injury
- IVDU
- Procedure
- Line placement

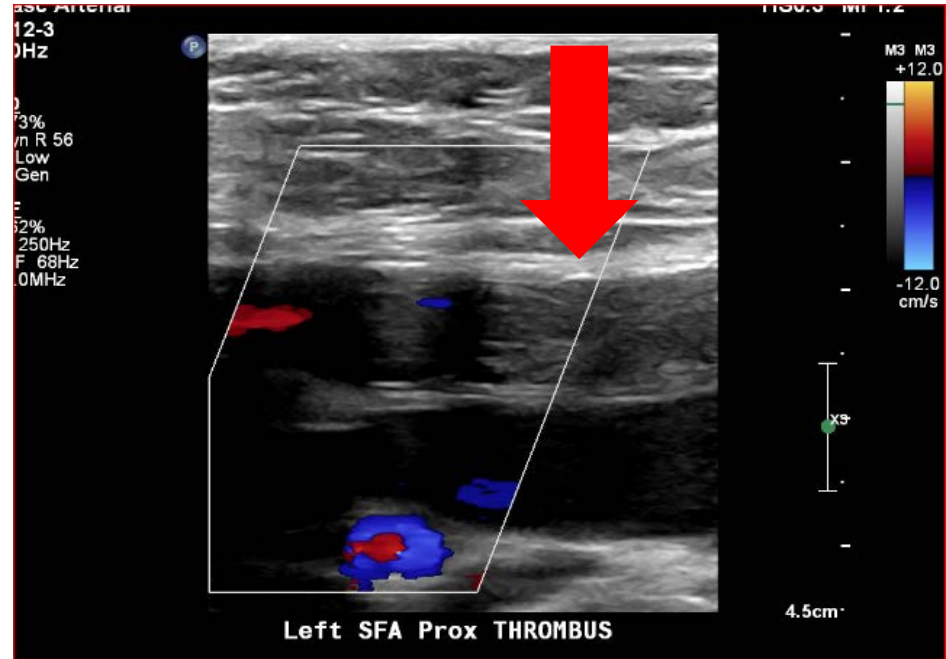
- Findings

- AV fistula
- Pseudoaneurysms
- DVT
- Hematoma
- Dissection/Intimal Flap
- Arterial Thrombus

# Vascular Injuries



Internal Carotid Artery Intimal Flap



Femoral Artery Thrombus

# Other Abdominal Studies

- Renal Artery
  - Stenosis
  - Fibromuscular Dysplasia
  - Stent Patency
- Superior Mesenteric Artery/Celiac
- Portal

# Thank-You



PACIFIC NORTHWEST  
ENDOVASCULAR  
CONFERENCE

[PNEC-SEATTLE.ORG](http://PNEC-SEATTLE.ORG)